

## Case report

# Cecal perforation due to angiostrongyliasis in an elderly patient

DOI: 10.5377/alerta.v6i1.15608

Rudecinda Ramírez Serrano

Salvadoran Institute of Social Security. San Salvador, El Salvador.

Correspondence

✉ rude\_1709@hotmail.com

0000-0002-9775-5375

## OPEN ACCESS

### Perforación cecal por angiostrongiliasis en un adulto mayor

#### Suggested citation:

Ramírez Serrano R. Cecal perforation due to angiostrongyliasis in an elderly patient. *Alerta*. 2023;6(1):18-24. DOI: 10.5377/alerta.v6i1.15608

#### Received:

October 13, 2022.

#### Accepted:

November 25, 2022.

#### Published:

January 30, 2023.

#### Author contribution:

RSR: study conception, manuscript design, literature search. Data collection, management and analysis, writing and editing.

#### Conflicts of interest:

No conflicts of interest.

#### Abstract

Abdominal angiostrongyliasis is a parasitic disease caused by the genus *Angiostrongylus costaricensis*, a nematode that infects humans through the secretions of snails or slugs, its definitive hosts. Costa Rica is considered the most endemic country, and it has been shown in different reviews that most cases occur in children and males. Case presentation. The patient was a 74-year-old woman who consulted for acute abdominal pain, with four days of evolution, accompanied by nausea, vomiting, and hyporexia. Laboratory tests reported mild leukocytosis and a negative general urine test. Abdominal ultrasonography reported a solid heterogeneous mass, poorly circumscribed in the right lateral abdomen, which led to the suspicion of acute appendicitis. **Treatment.** An exploratory laparotomy was performed, with the removal of a perforated colon tumor that spanned from the cecum to the proximal third of the ascending colon, in addition, a transverse ileum anastomosis was performed, without further complication. **Outcome.** She was managed with antibiotics and analgesics and was discharged nine days after the procedure, without complications. The biopsy showed parasite eggs consistent with *Angiostrongylus* sp.

#### Keywords

*Angiostrongylus* infections, *Angiostrongylus costaricensis*, intestinal perforation, cecum, appendicitis.

#### Resumen

La angiostrongiliasis abdominal es una enfermedad parasitaria causada por el género *Angiostrongylus costaricensis*, un nematodo que infecta a los humanos a través de las secreciones de caracoles o babosas; sus huéspedes definitivos. Costa Rica es el país que se considera más endémico, se ha evidenciado en distintas revisiones que la mayoría de los casos se presentan en niños y personas del sexo masculino. Presentación del caso. Se trata de una mujer de 74 años, que consultó por dolor abdominal agudo, de cuatro días de evolución, acompañado de náuseas, vómitos e hiporexia. Los exámenes de laboratorio reportaron leucocitosis leve y examen general de orina negativo. La ultrasonografía abdominal reportó una masa sólida heterogénea, mal circunscrita en flanco derecho, esto llevó a la sospecha de una apendicitis aguda. **Intervención terapéutica.** Se realizó una laparotomía exploradora, con la extirpación de una tumoración de colon perforado que abarcaba desde el ciego hasta el tercio proximal de colon ascendente, además, se realizó una anastomosis de íleo transversa, sin mayor complicación. **Evolución clínica.** Se manejó con antibióticos y analgésicos, fue dada de alta a los nueve días posteriores al procedimiento, sin complicaciones menores. La biopsia reportó huevos de parásitos consistentes con *Angiostrongylus* sp.

#### Palabras clave

Infecciones por *Angiostrongylus*, *Angiostrongylus costaricensis*, perforación intestinal, ciego, apendicitis.

## Introduction

Abdominal angiostrongyliasis (AA) is a parasitic disease caused by the genus *Angiostrongylus* which includes at least 20 species. Two etiological types are known to affect humans: *Angiostrongylus*

*cantonensis*, which specifically affects the central nervous system, and *Angiostrongylus costaricensis*, which causes abdominal angiostrongyliasis. It was described in 1971 by Morera and Céspedes. *A. costaricensis* is endemic to Costa Rica and is found in areas of the tropical America<sup>1</sup>.

*Angiostrongylus costaricensis* is a nematode with a complex life cycle, involving rodents as definite hosts and mollusk such as snails and slugs as intermediate hosts<sup>2</sup>. Incidentally, it infects humans, in whom its life cycle is not completed<sup>3</sup>. Humans are incidental hosts, therefore, the parasite is not able to complete its life cycle and the immature stages are not expelled in the feces, but the eggs accumulate in the arterioles that irrigate the affected tissue<sup>4</sup>. Infection in humans is generated by consuming food contaminated with the secretions of snails or slugs, or by handling them with the hands and subsequently putting them in the mouth. Slugs have been found on ripe fruits on the ground and on vegetables eaten raw<sup>2</sup>.

It was first described in 1971 in Costa Rica, then it was reported in different regions of the southern United States of America, Europe and countries of Latin America and the Caribbean<sup>5</sup>. The disease was first observed in Costa Rican children in 1952. According to Morera, more than 130 human cases of the disease had been discovered by 1971<sup>6</sup>. Subsequently, the rodent that acts as the natural definitive host and the mollusks that constitute the intermediate hosts were identified and their life cycle was clarified. The first non-Costa Rican case was found in Honduras in 1972 and the parasite has now been observed in most countries of the continent, from the United States to northern Argentina<sup>7</sup>.

In epidemiological terms, incidence or prevalence data are scarce; the actual prevalence of abdominal angiostrongyliasis has not been determined, and there is neither a coproparasitological test to confirm infection nor a serological "gold standard" test to ensure it<sup>8</sup>. Costa Rica is considered the most endemic country in the region, accounting for almost 90 % of the cases reported worldwide<sup>1</sup>. According to Frenkel, ten to 30 cases were diagnosed each year, mostly in children<sup>6</sup>. It is important to mention that in some Latin American countries only isolated data have been recorded; no prevalence data are available. From the epidemiological point of view, it has been shown in different reviews that most cases occur in children and males<sup>1</sup>.

In El Salvador between the years 2018 to 2021, 14 cases were reported, with ages ranging from two to 11 years old, mostly male, five from the central zone of the country, four from the paracentral zone, three from the western zone and two from the eastern zone. In-hospital stay was between two and eight days, with an average of two days. No data are available for adults<sup>9</sup>.

The incubation period varies from 14 days to several months. Humans become infected by eating contaminated food. Parasites and eggs are usually degenerated by host reaction, and eggs persist in human feces. The clinical presentation is varied and ranges from asymptomatic to severe manifestations requiring emergency surgery<sup>4</sup>. The clinical presentation is highly variable, making its diagnosis a challenge, symptoms such as malaise and myalgias are usually present in all cases, it can also present as an abdominal condition, which simulates acute appendicitis, associated with gastrointestinal symptoms and can be complicated with intestinal obstruction or perforation. It can also simulate a neoplasm. In laboratory studies, the most important finding is the presence of eosinophilia<sup>10</sup>.

A systematic review of cases reported that abdominal pain was present in 84 % of cases, vomiting in 50 %, diarrhea in 28 % and constipation in 14.2 %<sup>1</sup>. Surgical intervention remains the most effective strategy for the treatment of acute AA, as no convincing data have been obtained on the use of anthelmintic drugs<sup>4</sup>.

Much of the physiology of the parasite that causes the disease is unknown, as well as many epidemiological aspects, and after three decades of the description of this parasitosis, confirmation is only possible through histopathological material obtained after surgery. Currently, research continues on diagnostic tests, among the most recognized are the Morera test and the most current IgG and IgG1<sup>11</sup> antibodies. The Morera test is a qualitative test, consisting of latex agglutination, which started in the 1980s and is the test currently used in Costa Rica<sup>12</sup>.

The interest and concern that has motivated the study of *A. costaricensis* arises from the severity of the disease in humans, especially in school children and young adults, and the life cycle involving mollusks and rodents<sup>13</sup>.

## Case presentation

This is a 74 years old female patient from the municipality of San Martín, who consulted for pain in the epigastrium of four days of evolution, which was later located in the right iliac fossa, accompanied by nausea and vomiting; she did not report having presented fever, diarrhea and other symptoms, as well as having self-medicated with oral and intravenous n-butylthioscine and oral simethicone without improvement. The patient had a history of open cholecystectomy since three years ago. In addition, she had presented with alternating episodes of

constipation and diarrhea since six months before. Blood pressure of 120/70 mm Hg, heart rate of 95 beats per minute, respiratory rate of 16 breaths per minute and temperature of 37.6 °C. She was conscious, alert and oriented in time, place and person, with no signs of dehydration, the abdomen was symmetrical and presented pain at Mc Burney's point, with positive Rovsing and Infante Diaz signs; no rebound was identified at the time of evaluation.

Abdominal ultrasonography described distended bowel loops with moderate presence of gas predominantly in the right lower abdomen with a solid heterogeneous mass, not well circumscribed in the right flank measuring 6.1 cm x 4.0 cm x 4.9 cm, with a volume of 62.1 mL. It was suggested to rule out fecal impaction.

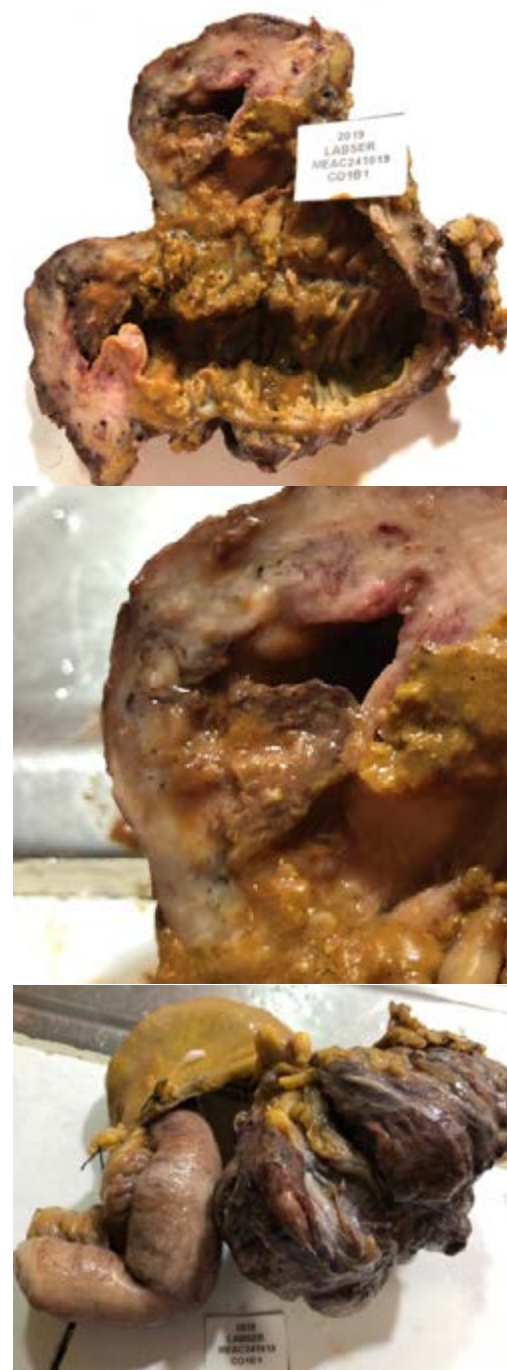Laboratory tests reported: leukogram: 8200 with 65.3 % neutrophils; hemoglobin: 10.8 g/dL; platelets: 431 000; prothrombin time: 11.8 seconds and thromboplastin time: 30.4 seconds. An acute abdomen is diagnosed, to rule out acute appendicitis versus cecal tumor.

## Surgical intervention

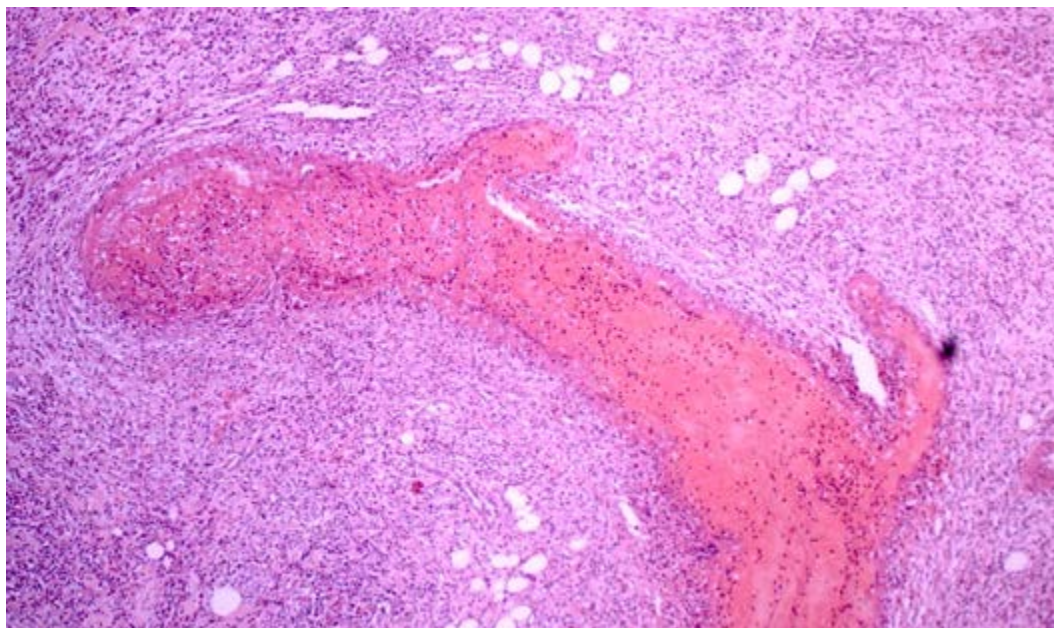
Surgery was performed four hours after admission. It started with a Rocky Davis incision; according to the findings it was decided to perform an exploratory laparotomy via the midline. 200 mL of peritoneal reaction fluid were identified, the cecum with a 10 x 10 cm perforated tumor accompanied by multiple mesentery nodes, the cecal appendix with inflammatory walls being completely removed (Figure 1). Subsequently, a right hemicolectomy was performed in which the tumor was removed together with the healthy limits, from ten cm anterior to the distal ileum to ten cm posterior to the hepatic flexure of the colon (Figure 1), in addition, the nodes located in the mesentery were dissected. The surgery was completed with a lateral end anastomosis performed with manual suture with Connell and Lembert stitches, hemostasis and complete count were verified.

On the third day of intrahospital stay, histopathological studies were reported. The macroscopic findings described the ileum of 14 x 3.5 cm, the cecum and ascending colon of 9 x 5 cm, with adhesions and hyperemia in the serosa; an area of 5 x 4 cm was found in the cecum, which thickened the wall in a one-centimeter layer with perforation towards the serosa. The cecal appendix was six cm with hyperemia of the serosa, which was obliterated when the lumen was cut. Microscopic find-

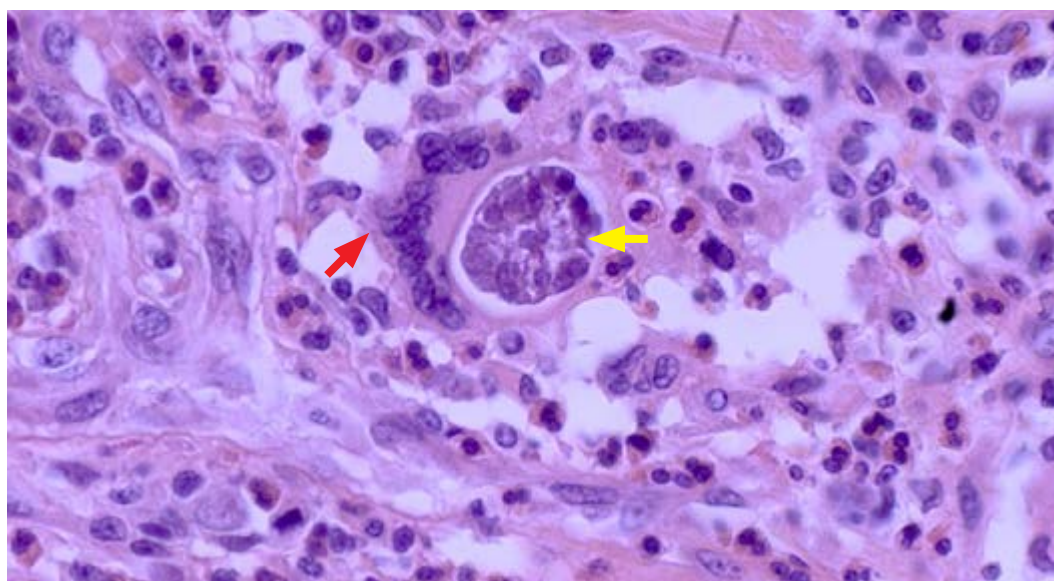
ings described acute suppurative inflammation and abundant eosinophilic infiltrate involving all layers with perforation into the serosa (Figure 2). In addition, parasite eggs consistent with *Angiostrongyloides sp.* were observed (Figure 3), located in the lumen of the capillaries and also diffusely arranged, some of them were surrounded by multinucleated foreign body-like giant cells. Thrombosed blood vessels and areas with hemorrhagic infarctions were also found. No larvae were present. The borders had inflammatory changes in the serosa. The cecal appendix with lumen obliteration by collagenous and spindle cells. Four to eight lymph nodes had fibrosis, eosinophils and



**Figure 1.** Macroscopic anatomical specimen: distal ileum, cecum and ascending colon



**Figure 2.** A thrombosed blood vessel is visualized under microscopy with hematoxylin-eosin stain (10x). The surrounding tissue shows a lymphoplasmacytic, eosinophilic and polymorphonuclear inflammatory infiltrate



**Figure 3.** Hematoxylin-eosin stained microscopy (40x) shows parasite eggs (yellow arrow) consisting of *angiostrongyloides* sp. surrounded by multinucleated foreign body-like giant cells (red arrow)

parasite eggs. There was no evidence of malignancy. The conclusion of the report was perforated angiostrongyliasis of the cecum. Fibrous obliteration of the cecal appendix, disseminated angiostrongyliasis in four of eight pericolic lymph nodes.

### Clinical evolution

The patient remained in the hospital for nine days. Oral feeding was suspended for 48 hours, providing intravenous maintenance fluids, with double antibiotic ceftriaxone and metronidazole, and adequate analgesia; in addition to transfusion of two units

of packed red blood cells. On the fifth day, upon receiving the biopsy report, treatment was started with ivermectin six mg orally every 12 hours for two days; on the seventh day, dehiscence of the aponeurosis of 20 % was observed, which was resutured without complications. At hospital discharge, laboratory tests showed negative blood cultures, negative general stool examination, hemoglobin of 10.9 and leukogram of 11 300 with 78.5 % neutrophils. The patient was evaluated in subsequent controls without abnormalities, the operative wound healed adequately. The last control was ten months later, without unidentified sequels.

## Clinical diagnosis

The clinicopathological diagnosis is established as abdominal angiostrongyliasis.

## Discussion

Regarding clinical presentation, general symptoms such as malaise and myalgias are usually present in all cases. A systematic review of case reports reported that abdominal pain was present in 84 % of cases, vomiting in 50 %, diarrhea in 28 % and constipation in 14.2 %. Generally, abdominal pain is localized in the right lower quadrant. Occasionally a painful mass or plastron can also be found there, which is often interpreted as complicated appendicitis or a neoplastic lesion<sup>1</sup>.

A case study published three years ago in Costa Rica suggests that the pathology can also be present with atypical symptoms, such as intestinal occlusions, which can lead to diagnostic but not therapeutic surgery<sup>14</sup>. In this case, a subject was reported with classic symptoms of intestinal obstruction that did not improve with medical treatment and that after 48 hours, due to the limitations of imaging studies in the health center, had to undergo diagnostic surgery, showing that there were areas of marked inflammation that led to a decrease in peristalsis, but there were no perforations or tumors that warranted a surgical procedure. Regarding the differential diagnosis it is easy to confuse the symptoms and signs of AA, because these are nonspecific, the main picture with which the confusion reported in the literature consulted is acute appendicitis, but other cases have also been reported in Europe as for example in which a patient presented with *A. cantonensis*, with abdominal pain on the fourth day of the disease. Surgical approach was discouraged by means of imaging studies and alprazolam and antihistamines (bilastin) were added to the treatment, obtaining an excellent clinical response, with disappearance of the symptoms in the following four to five days<sup>14</sup>.

In the literature reviews made in different Central American countries, eosinophilia is one of the main laboratory abnormalities in the leukogram report in AA cases, which may show more than 35 000 with eosinophilia of more than 10 % of cells. Nonetheless, eosinophilia is not specific to AA, since it can be reported in all parasitosis and other pathologies. It is defined as an absolute count of 500 eosinophils/microliter in peripheral blood. In a study carried out in Honduras, in a sample of 100 % of the entire population of selected children with an eosinophilia greater than 10 %, 45 % was associated with parasitosis<sup>15</sup>.

The Morera test which is a qualitative latex particle agglutination test. In a study conducted in Colombia in 2018, a new multiplex qPCR was analyzed for the specific, sensitive and simultaneous identification of *Angiostrongylus* species of importance in human and animal health. This test worked *in vitro*, becoming a new alternative for the diagnosis of angiostrongyliasis. However, it had yet to be validated in the field and in the clinic in patients and hosts in which parasite DNA was detected<sup>16</sup>.

Laparoscopic intervention for the acute abdomen of difficult diagnosis such as AA is a safe, feasible, and effective alternative, avoids extensive preoperative investigations or delays in surgical intervention, can help to prevent unnecessary non-therapeutic laparotomies and provide guidance in choosing the appropriate incision in patients in whom a definitive treatment cannot be completed laparoscopically.

These characteristics make laparoscopy a better option than open surgery in the management of abdominal emergencies<sup>17</sup>.

In the case presented, in which clinical findings were localized but not access to the laparoscopic approach, a less invasive approach was chosen; therefore, a Rocky Davis incision was started and decided to continue with midline exploratory laparotomy when there were findings that involved more than the base of the cecum<sup>18</sup>.

Some anatomopathological studies have revealed that the most frequently affected organs are the appendix, ileum, colon and surrounding lymph nodes. In a series of cases in which 90 patients underwent surgery, 36 had involvement of a single organ (colon, ileum, or appendix) and 25 had involvement of at least three segments (colon, appendix, and cecum). Only two cases involved the cecum and sigmoid while one case had disseminated disease<sup>4</sup>. Its affinity for the ileocecal region provokes a granulomatous reaction that causes abdominal pain, obstruction and even perforation; this is known as eosinophilic peritonitis, as mentioned above.

Although the ileocecal location is the most frequent, there may be independent involvement of the terminal ileum, cecum, appendix, or ascending colon. Two macroscopic presentations have been described: pseudoneoplastic, characterized by thickening of the intestinal wall, and congestive ischemia with the presence of necrotic lesions<sup>17</sup>.

Despite developments in the basic understanding of the biology and transmission of the disease, very few improvements have been made in medical treatments such as chemotherapy. Clinical attempts

lack good controls, as parasitological criteria for cure are not easy to establish, especially knowing that the infection can probably be self-limiting in most humans. Experimental chemotherapy trials with thiabendazole, albendazole, ivermectin, santonin, milbemycin D, mebendazole and with as yet undisclosed novel compounds such as PF1022A have been conducted in both *A. cantonensis* and *A. costaricensis*, with variable effects on either larval or adult stages. It is clear that chemotherapy and attempts with new drugs must be improved, since it is a disease that can be fatal<sup>12</sup>.

Surgical intervention remains the most effective strategy for the treatment of acute AA, since no convincing data have been obtained on the use of anthelmintic drugs, it should be treated according to the surgical guidelines for appendiceal neoplasms, where masses limited to the appendix should be treated with appendectomy and masses larger than two centimeters in diameter should undergo right hemicolectomy, including appendiceal resection<sup>17</sup>.

It is extremely important to educate the general population about the correct disinfection of fruits and vegetables before consumption and to raise awareness about the potential transmission of parasites through raw foods<sup>4</sup>. In the case presented we can observe a broad correlation with the literature in terms of clinical presentation and anatomopathological findings, where multiple organs were involved from the cecal appendix, cecum, and ascending colon. Histologically, there was eosinophilic infiltration of the intestinal mucosa and submucosa, as well as granuloma formation with ileocecal obstruction and necrosis. The treatment indicated in the literature showed a satisfactory clinical evolution despite the patient's age being a risk factor for post-operative complications.

AA represents a diagnostic challenge for many reasons, one of them is that although it is not a new disease, at the moment there is not a specific preoperative test that can be used, thus, the diagnosis is made after treatment. Knowledge and reporting of this disease should be increased, because it causes high morbidity, and can be prevented through education to the population, strengthening the knowledge of health personnel and the population in general.

## Ethical Aspects

The case presented complied with the Declaration of Helsinki and the provisions of the international ethical guidelines for research, was submitted to the hospital's

quality control department, and the confidentiality of the information will be safeguarded and protected. The consent of the patient and a family witness was requested, explaining all the beneficial aspects that the information of the clinical case will contribute to public health.

## Acknowledgments

To the staff of the Suchito National Hospital for their support in the diagnosis of the case and in the preparation of the article.

## Funding

No external funds were received for this work.

## References

1. Reynosa Aguilar Y, Elías Armas KS, Vega Puentes JO, Céspedes Pereña V. El riesgo de parasitismo por *Angiostrongylus cantonensis*: una problemática reemergente en Cuba. *Rev. inf. cient.* 2020;99(2):178-187. Available in: [http://scielo.sld.cu/scielo.php?script=sci\\_arttext&pid=S1028-99332020000200178&lng=es](http://scielo.sld.cu/scielo.php?script=sci_arttext&pid=S1028-99332020000200178&lng=es)
2. de Kaminsky R. Situación actual de *angiostrongylus costaricensis* y la infección en humanos y animales en las Américas. *Revista Médica Hondureña.* 1996;64(4):139-147. Available in: <https://revistamedicahondurena.hn/assets/Uploads/Vol64-4-1996-5.pdf>
3. Bolaños F, Jurado-Zambrano LF, Luna-Tavera RL, Jiménez JM. Abdominal angiostrongyliasis, report of two cases and analysis of published reports from Colombia. *Biomedica.* 2020 Jun 15;40(2):233-242. DOI: [10.7705/biomedica.5043](https://doi.org/10.7705/biomedica.5043)
4. Araya RA, Quesada LL, Vargas VH. Angiostrongilosis abdominal. *Rev Med Cos Cen.* 2015;72(617):711-718. Available in: <https://www.medigraphic.com/cgi-bin/new/resumen.cgi?IDArticulo=67168>
5. Maradiaga, Ramón Yefrin, et al. "Características de Angiostrongilosis Abdominal en Honduras." *Revista de la Facultad de Ciencias Médicas* 15.1 (2018): 36-42. Available in: [https://www.researchgate.net/profile/ramon-maradiaga-2/publication/334272723\\_caracteristicas\\_de\\_angiostrongilosis\\_abdominal\\_en\\_honduras/links/5d200ac4a6fdcc2462c413b2/caracteristicas-de-angiostrongilosis-abdominal-en-honduras.pdf](https://www.researchgate.net/profile/ramon-maradiaga-2/publication/334272723_caracteristicas_de_angiostrongilosis_abdominal_en_honduras/links/5d200ac4a6fdcc2462c413b2/caracteristicas-de-angiostrongilosis-abdominal-en-honduras.pdf)
6. Zúñiga SR, Cardona V, Alvarado D. Angiostrongilosis abdominal. *Rev Med Hondur* 51. 1983;51(4):184-92. Available in: <http://cidbimena.desastres.hn/RMH/pdf/1983/pdf/Vol51-4-1983-8.pdf>

7. Morera P, Amador J. Prevalencia de la angiostrongilosis abdominal y la distribución Estacional de la precipitación. *Revista Costarricense de Salud Pública*. 1998;7(13):1-14. Available in: [https://www.scielo.sa.cr/scielo.php?pid=S1409-14291998000200002&script=sci\\_arttext](https://www.scielo.sa.cr/scielo.php?pid=S1409-14291998000200002&script=sci_arttext)
8. Vargas M, Campos E, Mata C, Tijerino A. Evaluación de test de Morera según resultados del Centro Nacional de Referencia de Parasitología- Inciensa. Costa Rica enero 2012 - abril 2020. San José. Instituto Costarricense de Investigación y Enseñanza en Nutrición y Salud. 2020. 10 p. Disponible en: [https://www.inciensa.sa.cr/vigilancia\\_epidemiologica/informes\\_vigilancia/2020/CNR%20Parasitologia/Informe%20Tecnico%20A.%20costarricensis.pdf](https://www.inciensa.sa.cr/vigilancia_epidemiologica/informes_vigilancia/2020/CNR%20Parasitologia/Informe%20Tecnico%20A.%20costarricensis.pdf)
9. Ministerio de Salud de El Salvador. Sistema de Morbimortalidad en Línea. Ministerio de Salud. 2023. Consulted date: 3 de marzo de 2022. Available in: <https://simmow.salud.gob.sv/>
10. Hernández Ros B, De Paz H, Medina P, Chávez P. Diagnóstico de *Angiostrongylus costaricensis* en biopsia endoscópica de colon. *Rev. méd. (Col. Méd. Cir. Guatem.)*. 2021;160(2):179-181. DOI: [10.36109/rmg.v160i2.359](https://doi.org/10.36109/rmg.v160i2.359)
11. Abrahams Sandí E. Angiostrongiliasis abdominal: notas sobre el diagnóstico. *Revista Biomedica*. 2007;18(1):37-45. Available in: <https://www.revistabiomedica.mx/index.php/revbiomed/article/view/474>
12. Navarro CJF, Ledezma CA. Oclusión Intestinal por *Angiostrongylus costaricensis*. Revisión Bibliográfica y Reporte de un caso. *Rev Clin Esc Med*. 2019;9(1):72-79. Available in: <https://www.medigraphic.com/pdfs/revcliescmed/ucr-2019/ucr191i.pdf>
13. Rojas A, Maldonado Junior A, Mora J, Morassutti A, Rodríguez R, Solano-Barquero A, et al. Angiostrongiliasis abdominal en las Américas: cincuenta años desde el descubrimiento de una nueva especie de metastrongilido, *Angiostrongylus costaricensis*. *Vectores de parásitos. Parasites Vectors*. 2021;14(1):374. DOI: [10.1186/s13071-021-04875-3](https://doi.org/10.1186/s13071-021-04875-3)
14. Valerio Sallent L, Moreno Santabarbara P, Roure Díez S. Abdominal pain secondary to neuroinvasive *Angiostrongylus cantonensis*; first European case. Some reflections on emerging parasitosis. *Gastroenterología y Hepatología*. 2021;44(8):566 - 567. DOI: [10.1016/j.gastre.2020.07.021](https://doi.org/10.1016/j.gastre.2020.07.021)
15. Espinoza LM, Soto RJ, Alger J. Eosinofilia asociada a helmintiasis en niños. *Rev Mex Patol Clin Med Lab*. 1999;46(2):79 - 85. Available in: <https://www.medigraphic.com/pdfs/patol/pt-1999/pt992e.pdf>
16. Varela MRE, Arias JS, Velásquez LE. Estandarización de una prueba múltiple de reacción en cadena de la polimerasa en tiempo real para la identificación de *Angiostrongylus cantonensis*, *A. costaricensis* y *A. vasorum*. *Biomedica*. 2018;38(1):111. DOI: [10.7705/biomedica.v38i0.3407](https://doi.org/10.7705/biomedica.v38i0.3407)
17. Rivas Méndez D, Palmisano M E, González Contreras Q, Oliva Catalán G. Angiostrongilosis abdominal. *Cirujano General*. 2015;37(3-4):105 -108. DOI: [10.35366/65760](https://doi.org/10.35366/65760)
18. Sharaf MF, Ghalwash ET, Ali AARM. Role of Laparoscopy in Diagnosis and Treatment of Acute Abdominal Pain. *The Egyptian Journal of Hospital Medicine*. 2020;79(1):442- 445. DOI: [10.21608/ejhm.2020.80838](https://doi.org/10.21608/ejhm.2020.80838)